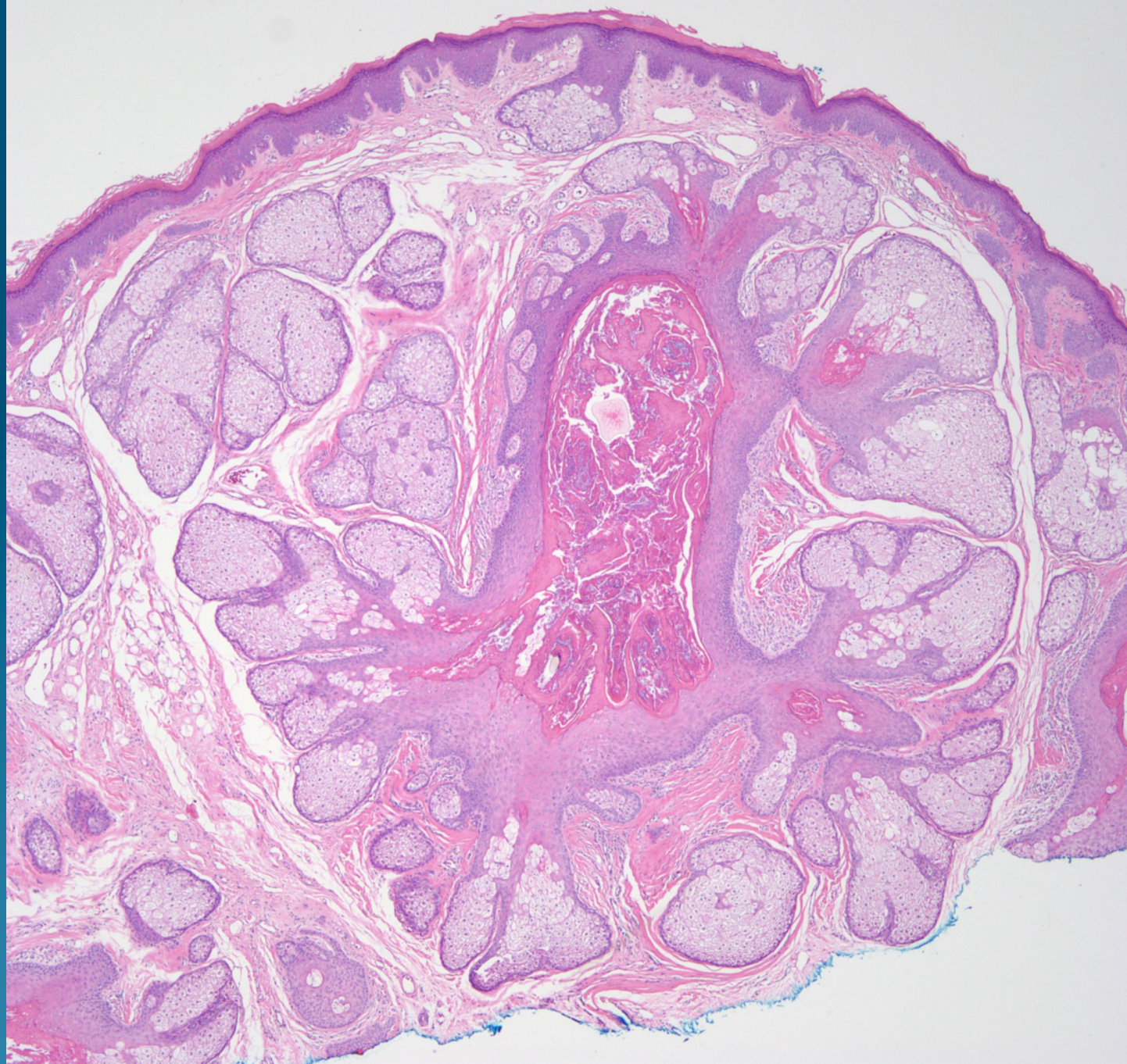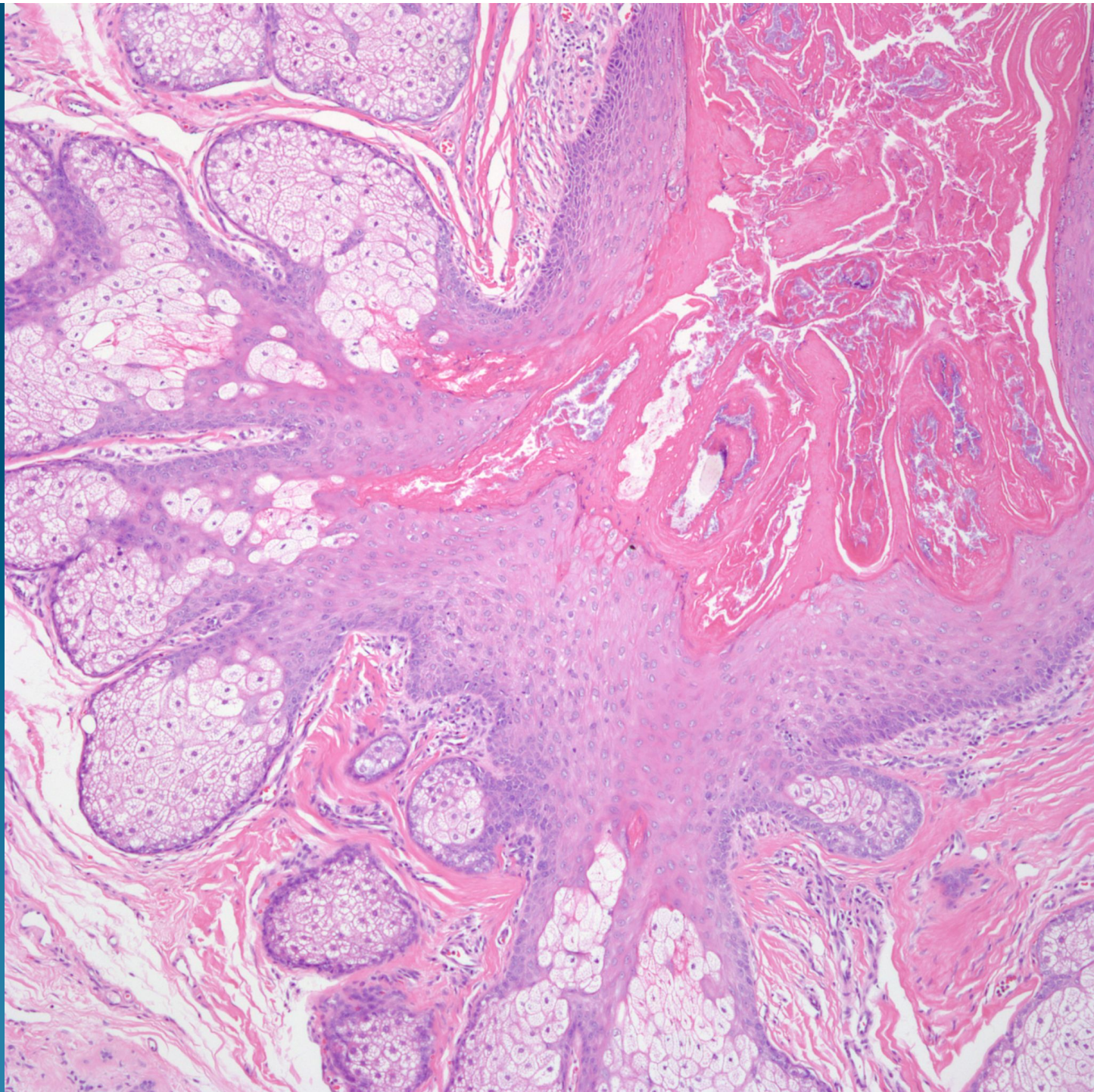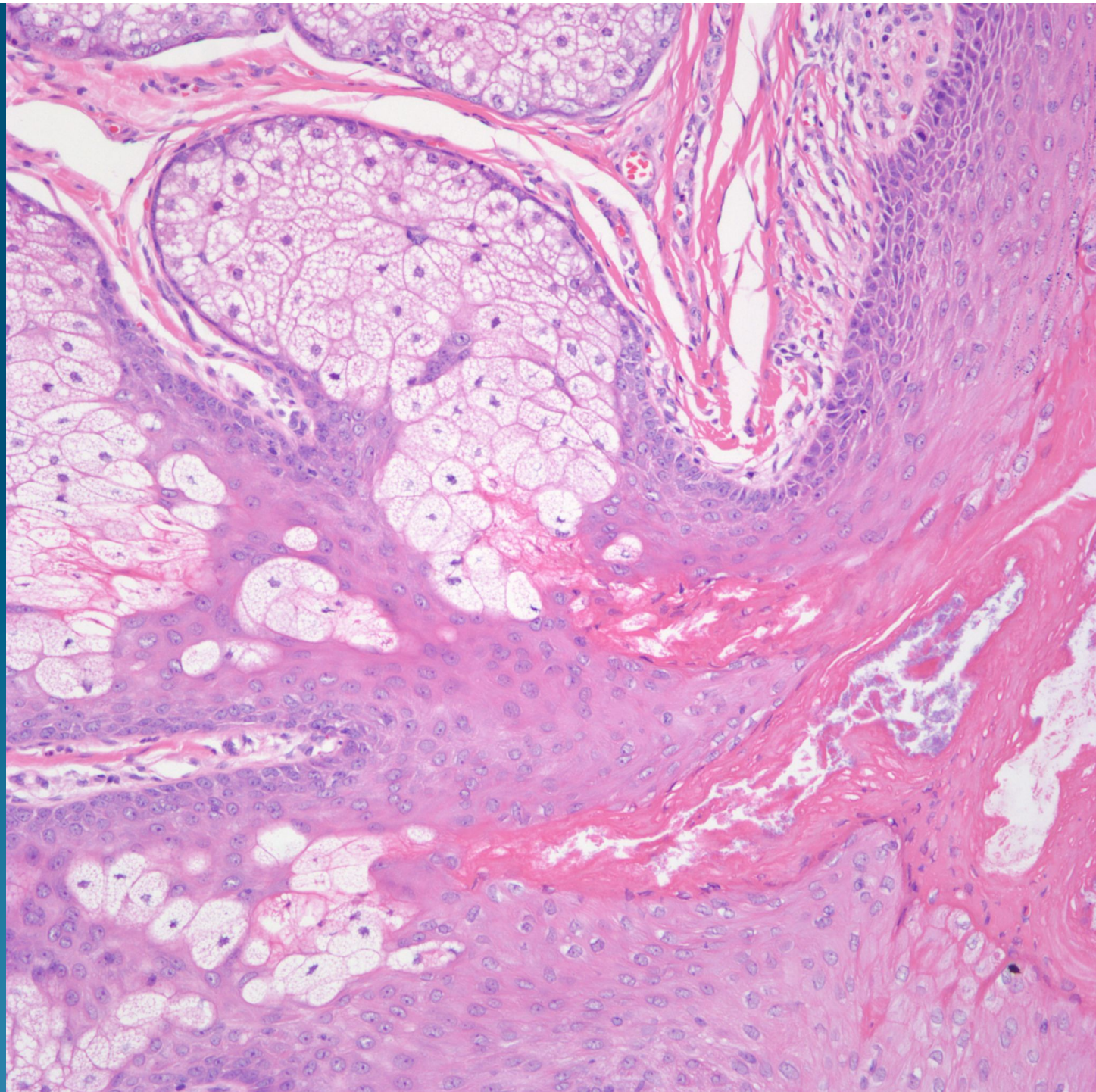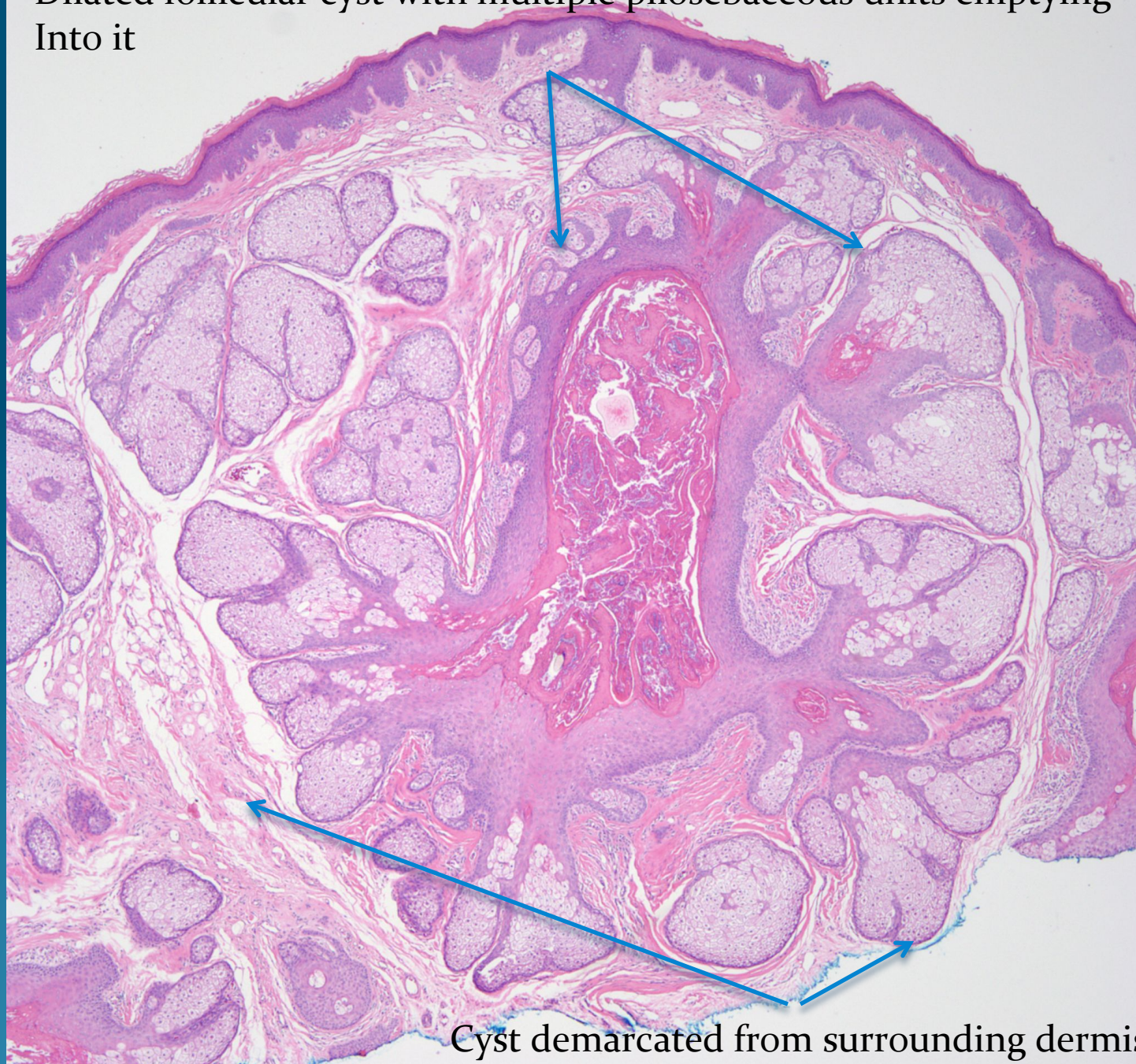


# What is the best diagnosis?

- A. Trichoepithelioma
- B. Trichoadenoma
- C. Trichilemmoma
- D. Trichoblastoma
- E. Trichofolliculoma



Dilated follicular cyst with multiple pilosebaceous units emptying  
Into it



Cyst demarcated from surrounding dermis